

CLINICAL REPORT

## Conservative orthodontic-prosthetic approach for excessive gingival display: A clinical report



Rafael del Castillo, DDS,<sup>a</sup> Ana M. Hernández, MD, DDS,<sup>b</sup> and Carlo Ercoli, DDS<sup>c</sup>

A differential diagnosis of excessive gingival display is essential for determining treatment strategies, because treatments can vary considerably depending on the cause of the excessive display. Clinicians must identify whether excessive gingival display is present only in the anterior sextant or affects the entire arch.<sup>1</sup> In the latter situation, it may be the result of vertical maxillary excess.<sup>2</sup> If all maxillary teeth have super-erupted, treatment may require a combination of orthodontics and orthognathic surgery to move the entire maxilla apically and/or an extensive crown lengthening procedure.<sup>3,4</sup>

A second potential cause for the excessive gingival display is delayed apical migration of the gingival margin. In some patients, this tissue may be thick and fibrotic with 3- to 4-mm probing depths. These individuals could benefit from gingival surgery to displace the gingival margin apically toward the cemento-enamel junction.<sup>5</sup>

A third possible cause is tooth malposition, which generally occurs in those diagnosed with Angle class II, division 2 malocclusion. As a consequence of the unfavorable anteroposterior and labiolingual position of the maxillary canines, these teeth may not provide the adequate disclusion of posterior teeth seen in normal mutually protected occlusion.<sup>6,7</sup> Moreover, disclusion during protrusion is primarily borne by the maxillary central incisors with occasional contact of the lateral

### ABSTRACT

A differential diagnosis of excessive gingival display is critical in determining appropriate treatment options and sequence. Anterior tooth malposition for patients with deep vertical overlap has been suggested as one of the 3 main causes of excessive gingival display. Specifically, patients with Angle class II, division 2 malocclusions show an occlusal scheme that might be responsible for additional anterior tooth wear when compared with individuals without malocclusion. In the long term, this condition can cause dentoalveolar compensation and overeruption of maxillary incisors with concomitant coronal movement of the gingival margin with excessive gingival display. A combined orthodontic and restorative treatment was proposed as a conservative treatment to reposition maxillary anterior teeth and their gingival margins to a more ideal position and create the necessary interocclusal restorative space to restore worn teeth with ceramic restorations, enhance dental and facial esthetics, and reestablish anterior guidance. (J Prosthet Dent 2015;114:3-8)

incisors, thereby increasing the possibility of wear of the maxillary central incisors.<sup>8</sup> Additionally anterior tooth wear can be exacerbated by attrition and/or erosion.<sup>9</sup>

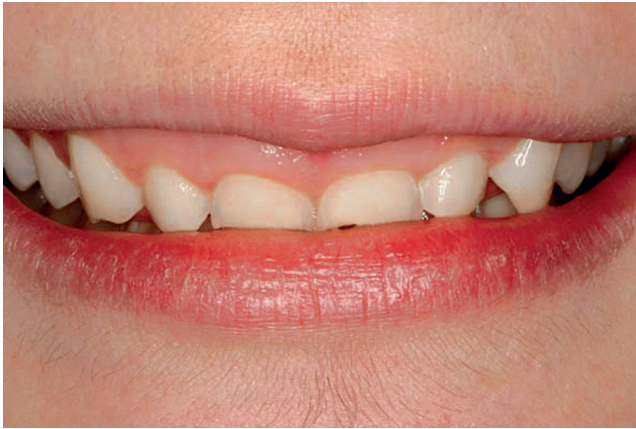Although enamel softening is generally not clinically detectable, erosion decreases the wear resistance of dental hard tissue.<sup>10</sup> As a consequence, erosion can be exacerbated in vivo by mechanical abrasion such as tooth brushing, after an acid challenge, or by attrition caused by tooth-to-tooth contact.<sup>11</sup>

In Angle class II, division 2 malocclusions, in which tooth wear is localized in the maxillary anterior teeth, clinicians may observe dentoalveolar compensation<sup>12</sup> and supereruption of the maxillary incisors with concomitant coronal movement of the gingival margin. This clinical report describes a multidisciplinary orthodontic-prosthetic treatment approach for the rehabilitation of a patient affected by excessive maxillary gingival display secondary to the presence of Angle class II, division 2 malocclusions and localized anterior tooth wear.

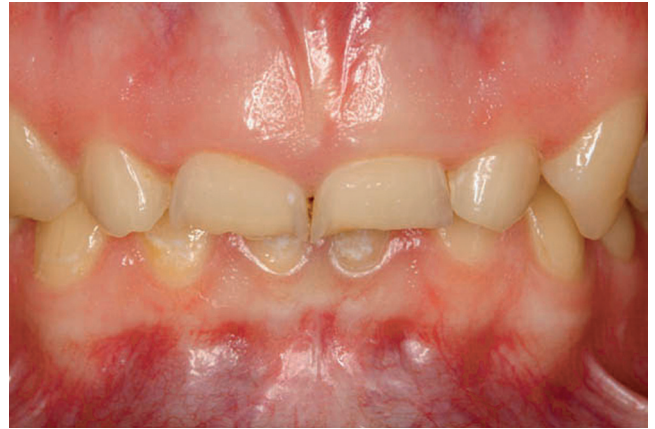<sup>a</sup>Clinical Assistant Professor, Division of Prosthodontics, Eastman Institute for Oral Health, University of Rochester, Rochester, NY.

<sup>b</sup>Private practice, Alicante, Spain.

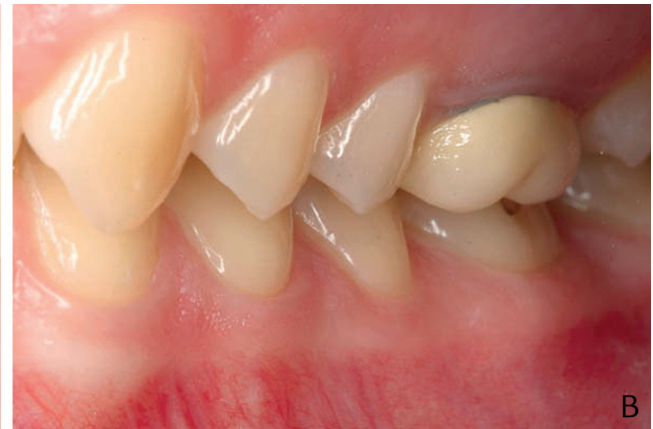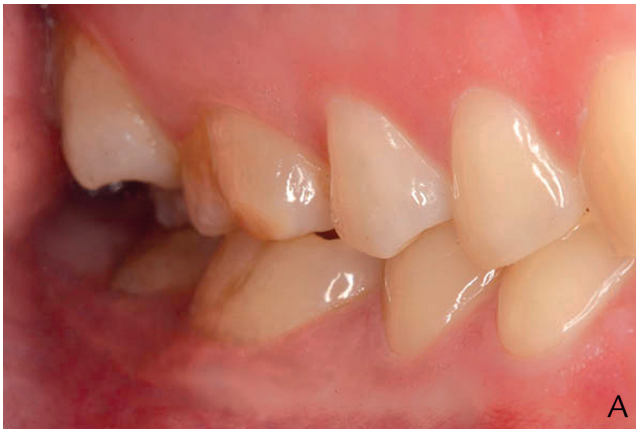<sup>c</sup>Professor, Chairman, and Program Director, Division Of Prosthodontics, Eastman Institute for Oral Health, University of Rochester, Rochester, NY.



**Figure 1.** Esthetic analysis shows normal tooth exposure at rest and flat maxillary incisal plane both at rest and during smile. Excessive gingival display is apparent during smile.



**Figure 2.** Width/length proportion of maxillary anterior teeth was severely altered by wear. Maxillary central and lateral incisors gingival levels show discrepancy with respect to maxillary canines.



**Figure 3.** A, Pretreatment lateral views show malocclusion in maxillary right second molar. B, Maxillary left first molar shows pretreatment metal ceramic restoration.

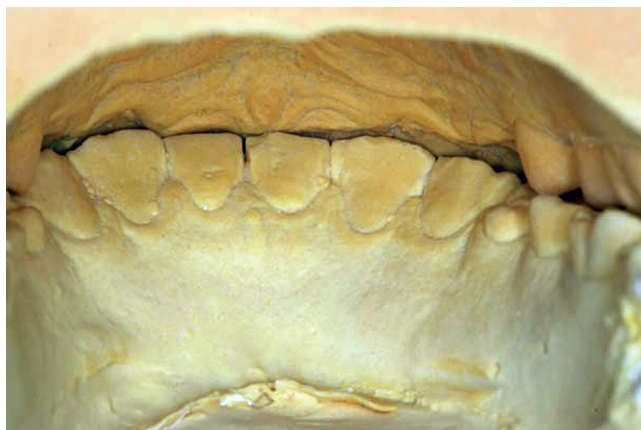## CLINICAL REPORT

A 28-year-old woman presented for clinical examination at a private clinic in Alicante, Spain. The patient's chief complaints were mild tooth hypersensitivity and dissatisfaction with her dental esthetics. Her dental history was significant for a lemon sucking habit during adolescence, self-reported nocturnal bruxism, and a base metal alloy allergy.

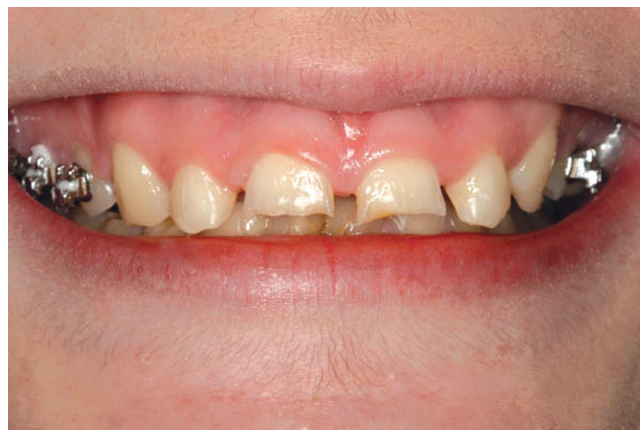An intraoral clinical examination revealed advanced wear and the supereruption of the maxillary central and lateral incisors coupled with localized excessive gingival display. The mandibular anterior teeth and first premolars showed the loss of buccal enamel surface without dentin exposure. The mandibular central incisors presented endodontic treatment, recurrent caries under mesial and distal composite resin restorations, and sensitivity to pressure. The maxillary left first molar had an ill-fitting metal ceramic restoration with recurrent caries.

Extraoral and intraoral clinical photographs were made to analyze esthetics. These showed normal tooth exposure at rest and during smiling (Fig. 1), a flat maxillary incisal plane following the natural concavity of the lower lip at rest and during smiling, and a medium smile line with a marked discrepancy of maxillary central and lateral incisor gingival levels with respect to the canines. The width/length proportion of the maxillary anterior teeth was severely altered. Facial and dental midlines were found to be coincident (Fig. 2). Probing depths of maxillary teeth were 1 to 2 mm.

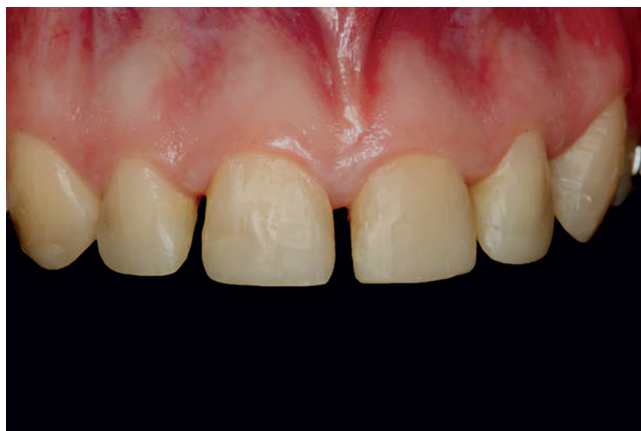The patient was characterized as a brachyfacial type. Cephalometric analysis of pretreatment lateral telerradiography showed a skeletal class II. A pretreatment diagnostic cast analysis showed a normal mandibular arch, an Angle dental class II, division 2 malocclusion on the left side, and a mild malocclusion in the maxillary right second molar (Fig. 3). The diagnostic mounting of pretreatment diagnostic casts in a semiadjustable



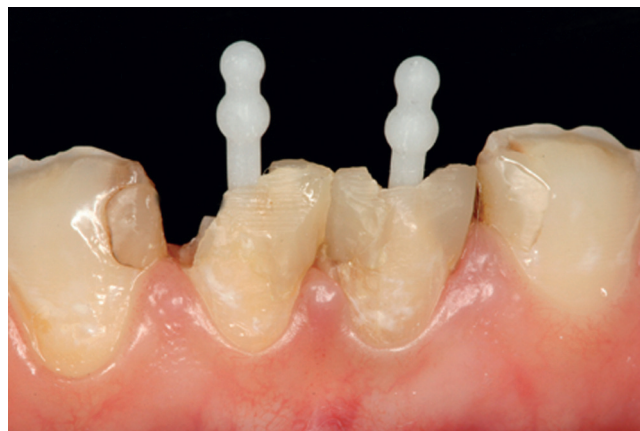**Figure 4.** Lingual view of pretreatment study casts show absence of adequate interocclusal restorative space between maxillary and mandibular anterior teeth.



**Figure 5.** Diastemas and slight protrusion of maxillary anterior teeth were obtained with orthodontics to facilitate initial restorative procedures.



**Figure 6.** Interim restoration of maxillary anterior teeth with microhybrid composite resin to evaluate esthetics, phonetics, and occlusal stability.



**Figure 7.** Mandibular central incisors retreated endodontically and restored with fiber/resin posts and direct composite resin restorations.

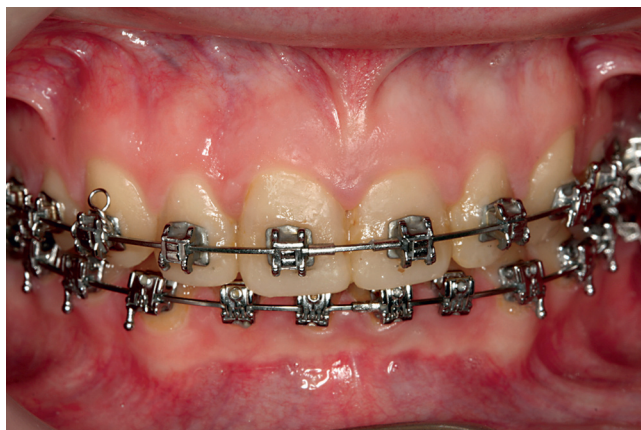articulator displayed the absence of adequate inter-occlusal restorative space between the maxillary and mandibular anterior teeth (Fig. 4). The determination of the ideal treatment option was based on several criteria: tooth and gingival exposure at rest and during smiling, position of the incisal edge relative to the lower lip, tooth size and proportion, root shape and length, periodontal support, and preservation and/or reestablishment of the anterior guidance. The objectives of the treatment were to establish the proper tooth position and inclination with canine Angle class I occlusion, correct malocclusion of the maxillary right second molar, intrusion of the maxillary central and lateral incisors to recreate adequate restorative interocclusal space, and the apical repositioning of the gingival margin of the same teeth to improve gingival esthetics.

During the initial phases of the orthodontic treatment, the maxillary left first premolar was extracted, the maxillary left canine was distally displaced to accomplish a canine class I occlusion, and the maxillary anterior teeth

were slightly protruded to create diastemas between them (Fig. 5). Orthodontic brackets were then removed, and the maxillary anterior teeth were provisionally restored with microhybrid composite resin (G-aenial; GC Corp) (Fig. 6). The mandibular central incisors were endodontically retreated and restored with fiber/resin posts (ParaPost Fiber White; Coltène/Whaledent Inc) and direct composite resin restorations (G-aenial; GC Corp) (Fig. 7).

Orthodontic treatment then continued to correct the malocclusion of the maxillary right second molar and intrude the maxillary central and lateral incisors to apically reposition their gingival margins. To establish the necessary amount of intrusive movement on the maxillary central and lateral incisors and the right canine, the maxillary left canine gingival margin was used as a reference. Brackets on maxillary central incisors and right canine were placed to level their gingival margins with that of the maxillary left canine. Brackets on the maxillary lateral incisors were placed to position their gingival





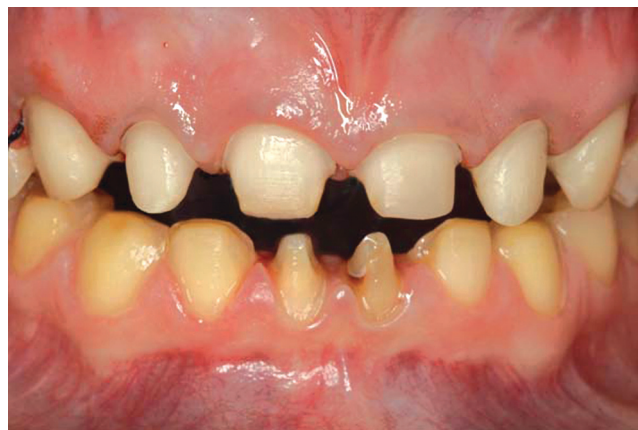**Figure 8.** Composite resin was added again to maxillary canines and central and lateral incisors to restore them to anatomic contour, allowing orthodontic movement to be completed.

margins 1 mm more coronal after the intrusive movement was completed. In addition, composite resin was added only to the cingulums of the maxillary central and lateral incisors to increase the occlusal vertical dimension (OVD), generating interocclusal space between the posterior teeth and unlocking the occlusion in lateral segments.

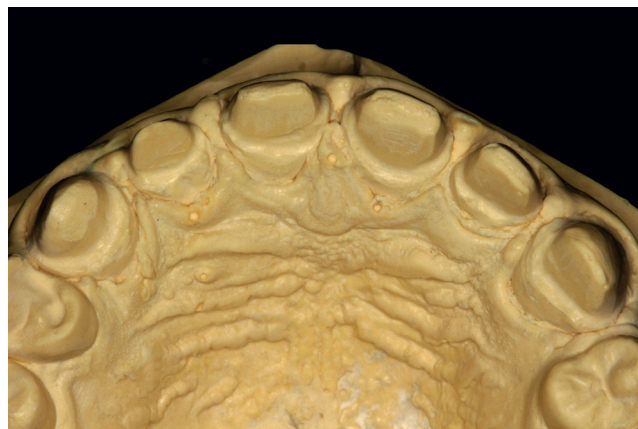As soon as orthodontic intrusion was completed, composite resin was again added to the teeth in the maxillary anterior sextant in order to restore them to anatomic contour. These interim composite resin restorations permitted an evaluation of esthetics, phonetics, and function before the definitive restorative treatment phase (Fig. 8).

After a 3-month verification of the patient's accommodation to the altered OVD and new esthetics and phonetics, the brackets were removed. New alginate impressions were made, and diagnostic casts were mounted on the articulator by means of a facebow record. A diagnostic waxing was completed based on ideal crown contours and esthetic parameters. Anterior composite resin restorations were removed and silicone indexes based on the waxing were used to guide the definitive tooth preparations.

Porcelain veneers were selected to restore tooth structural integrity, stiffness, and original biomechanical behavior.<sup>13-15</sup> A narrow shoulder preparation design<sup>16</sup> with incisal and interproximal wraparound was used for the maxillary anterior teeth.<sup>17</sup> This preparation design allowed the ceramist to design definitive restorations with optimal form and emergence profile. The preparation design for the mandibular right first premolar, canines, and lateral incisors, with a narrow chamfer finish line, followed the Type II indication for ceramic restorations as described by Magne and Belser<sup>17</sup> (Fig. 9). Definitive impressions were made by using a custom tray with the 1-step, double mix impression technique with a



**Figure 9.** Maxillary tooth preparations with slightly concave shoulder margins and smooth contours, avoiding sharp angles. Mandibular right first premolar, canines, and lateral incisors were prepared with narrow chamfer finish lines.



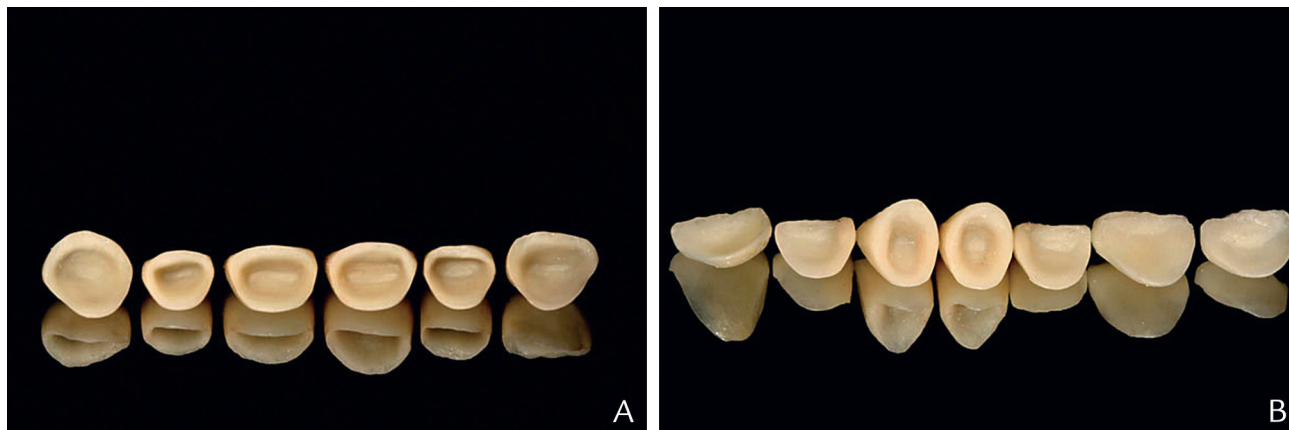
**Figure 10.** Occlusal views of tooth preparations show adequate occlusal and interproximal reduction for fabrication of definitive restorations.

vinyl-polyether silicone impression material (EXA'lence 370; GC Corp)<sup>18</sup> and a double cord (Ultrapak; Ultradent Products Inc) tissue displacement technique.<sup>19</sup> Definitive casts were fabricated with an improved Type IV dental stone and mounted in a semiadjustable articulator by means of new facebow and interocclusal records (Fig. 10).

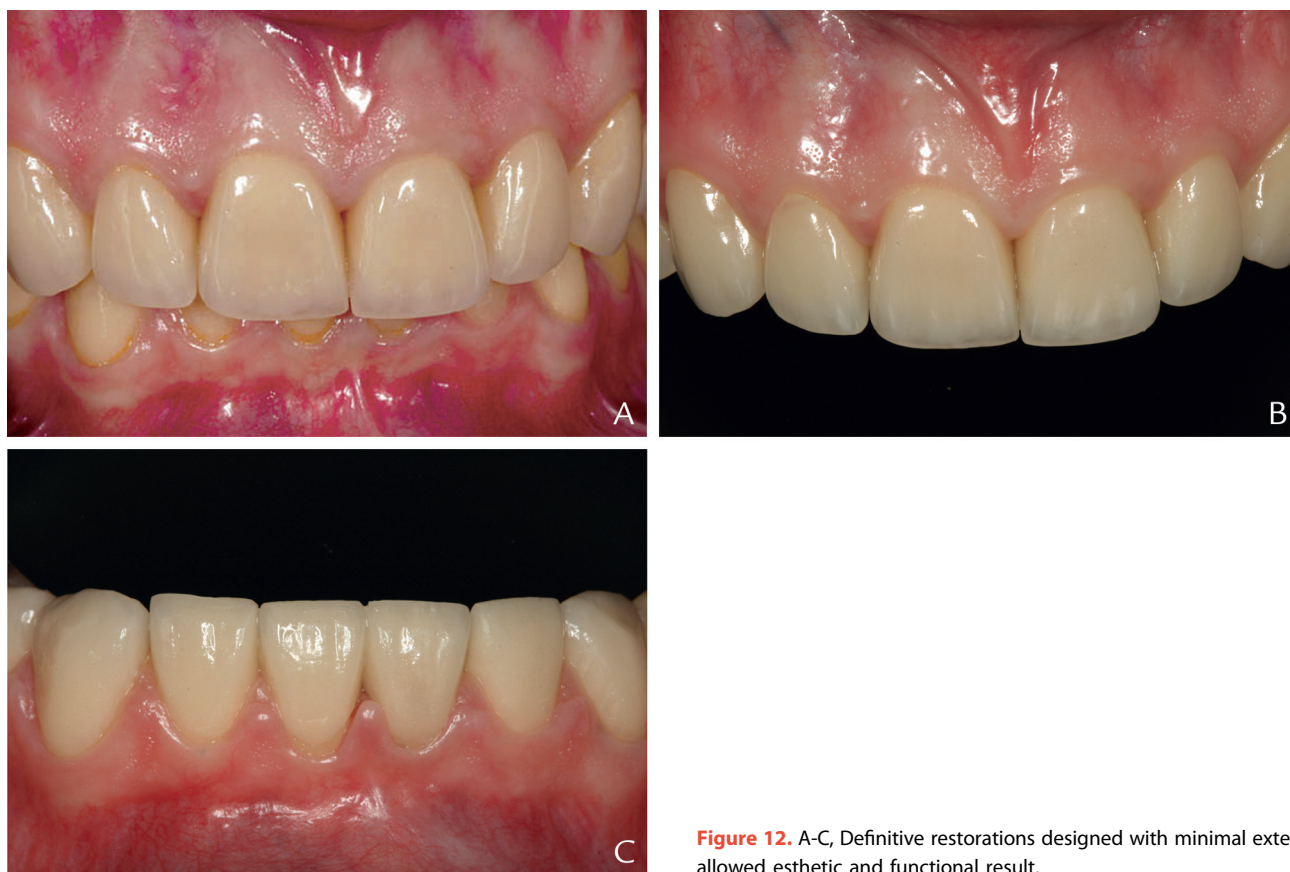Definitive feldspathic ceramic restorations (Fig. 11) were cemented with light-polymerizing adhesive resin cement (Variolink; Ivoclar Vivadent) and isolation with displacement cords and cotton rolls. A new metal ceramic restoration was fabricated for the maxillary left first molar (Figs. 12, 13).

## DISCUSSION

Differential diagnosis of tooth wear between chemical and mechanical etiology is often difficult. A combination of abrasion and erosion seemed to have caused the severe wear of the anterior teeth shown in the present



**Figure 11.** A, B, Restorations before cementation show differences in crown contours that depended on remaining intact tooth structure and definitive tooth anatomy.

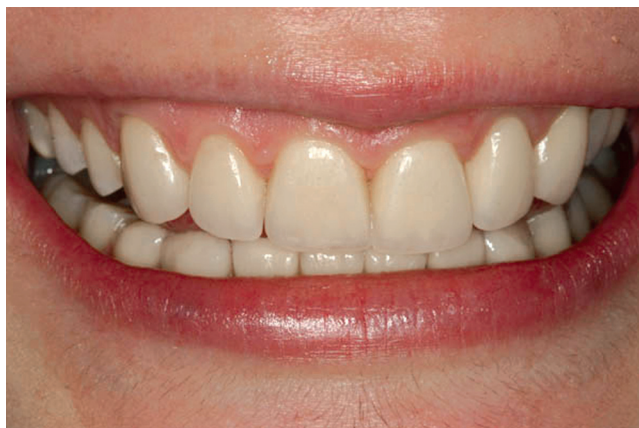

**Figure 12.** A-C, Definitive restorations designed with minimal extension allowed esthetic and functional result.

patient. Additionally, the occlusal scheme characterized by Angle class II, division 2 malocclusions could have exacerbated anterior tooth wear.

The use of orthodontics to intrude anterior teeth to allow for the overeruption of lateral segments, correct inadequate posterior occlusal relationship in the maxillary right second molar, and reestablish an

adequate interocclusal restorative space was considered a conservative alternative that minimized the extension of the restorations. The definitive occlusal plane and OVD were slightly different when compared with the OVD at the beginning of the treatment. Nevertheless, the slight increase of OVD and the reorientation of the occlusal plane did not



**Figure 13.** Completed restorations.

jeopardize the esthetic results but actually established a stable occlusion and a functional anterior guidance.

Possible alternatives to the chosen treatment plan included the surgical crown lengthening of the maxillary central and lateral incisors to reposition the gingival margins and expose a sufficient amount of tooth structure to allow for their restoration. However, the probing depths of the maxillary incisors were determined to be 1 to 2 mm, indicating that gingival surgery by itself would not have been sufficient to improve esthetics without adversely affecting the crown-to-root ratio and the periodontal support of these teeth.

## CONCLUSION

A conservative orthodontic-prosthetic approach was used to treat a patient with severe anterior tooth wear. This allowed for recovery of the structural integrity of the maxillary and mandibular anterior teeth, improved the dental and facial esthetics, and reestablished both the anterior guidance and a stable occlusion.

## REFERENCES

1. Kokich V. Anterior dental esthetics: An orthodontic perspective. II. Vertical relationships. *J Esthet Dent* 1993;5:174-8.
2. Willmar K. On LeFort I osteotomy. *Scand J Plast Reconstr Surg* 1974;12:1-68.
3. Proffit W, Phillips C. Adaptation in lip posture and pressure following orthognathic surgery. *Am J Orthod Dentofac Orthop* 1988;93:294-302.
4. Rosen H. Lip-nasal aesthetics following LeFort I osteotomy. *Plast Reconstr Surg* 1988;81:171-9.
5. Kokich V. Esthetics: the orthodontic-periodontic restorative connection. *Semin Orthod* 1996;2:21-30.
6. Roth RH. Functional occlusion for the orthodontist. Part I. *J Clin Orthod* 1981;15:32-51.
7. Roth RH, Rofis DA. Functional occlusion for the orthodontist. Part II. *J Clin Orthod* 1981;15:100-23.
8. Oltramari-Navarro P, Janson G, de Oliveira R, Quaglio C, Henriques J, Sales-Peres S, et al. Tooth-wear patterns in adolescents with normal occlusion and class II, division 2 malocclusion. *Am J Orthod Dentofacial Orthop* 2010;137:730.e1-5.
9. Walls A. Prevention in the aging dentition. In: Murray JJ, editor. *Prevention of role of disease*. New York: Oxford University Press; 1999. p. 173-88.
10. Davis WB, Winter PJ. The effect of abrasion on enamel and dentin after exposure to dietary acid. *Br Dent J* 1980;148:253-6.
11. Infield T. Dental erosion. Definition, classification and links. *Eur J Oral Sci* 1996;104:151-5.
12. Corthers A, Sandham A. Vertical height differences in subjects with severe dental wear. *Eur J Orthod* 1993;15:519-25.
13. Magne P, Versluis A, Douglas WH. Rationalization of incisor shape. Experimental numerical analysis. *J Prosthet Dent* 1999;81:345-55.
14. Magne P, Douglas WH. Porcelain veneers: Dentin bonding optimization and biomimetic recovery of the crown. *Int J Prosthodont* 1999;12:111-21.
15. Magne P, Douglas WH. Cumulative effect of successive restorative procedures on anterior crown flexure: intact versus veneered incisors. *Quintessence Int* 2000;31:5-18.
16. Magne P. Immediate dentin sealing. A fundamental procedure for indirect bonded restorations. *J Esthet Restor Dent* 2005;17:144-55.
17. Magne P, Belser U. *Bonded porcelain restorations in the anterior dentition*. Chicago: Quintessence Publishing Co; 2002. p. 129-76.
18. Tjan AH, Whang SB, Tjan AH, Sarkissian R. Clinically oriented evaluation of the accuracy of commonly used impression materials. *J Prosthet Dent* 1986;56:4-8.
19. Nemetz H, Donovan T, Landesman H. Exposing the gingival margin. A systematic approach for the control of the hemorrhage. *J Prosthet Dent* 1984;51:647-51.

## Corresponding author:

Dr Rafael del Castillo  
c/ Alfonso el Sabio 34, 2ºA  
Alicante, 03004  
SPAIN  
Email: [casher@infomed.es](mailto:casher@infomed.es)

Copyright © 2015 by the Editorial Council for *The Journal of Prosthetic Dentistry*.